



# Oral Pathology for the Physician

**Kristin K. McNamara, DDS, MS**

*Division of Oral and Maxillofacial Pathology  
The Ohio State University College of Dentistry  
[mcnamara.189@osu.edu](mailto:mcnamara.189@osu.edu)*

**MedNet21**  
Center for Continuing Medical Education

 **THE OHIO STATE UNIVERSITY**  
WEXNER MEDICAL CENTER

## Objectives

- Review the clinical features of oral candidiasis
- Reinforce differentiation of oral candidiasis from coated tongue
- Review the clinical features of common oral ulcers
- Recognize the clinical features of potentially malignant oral lesions.
- Update management strategies

## Outline

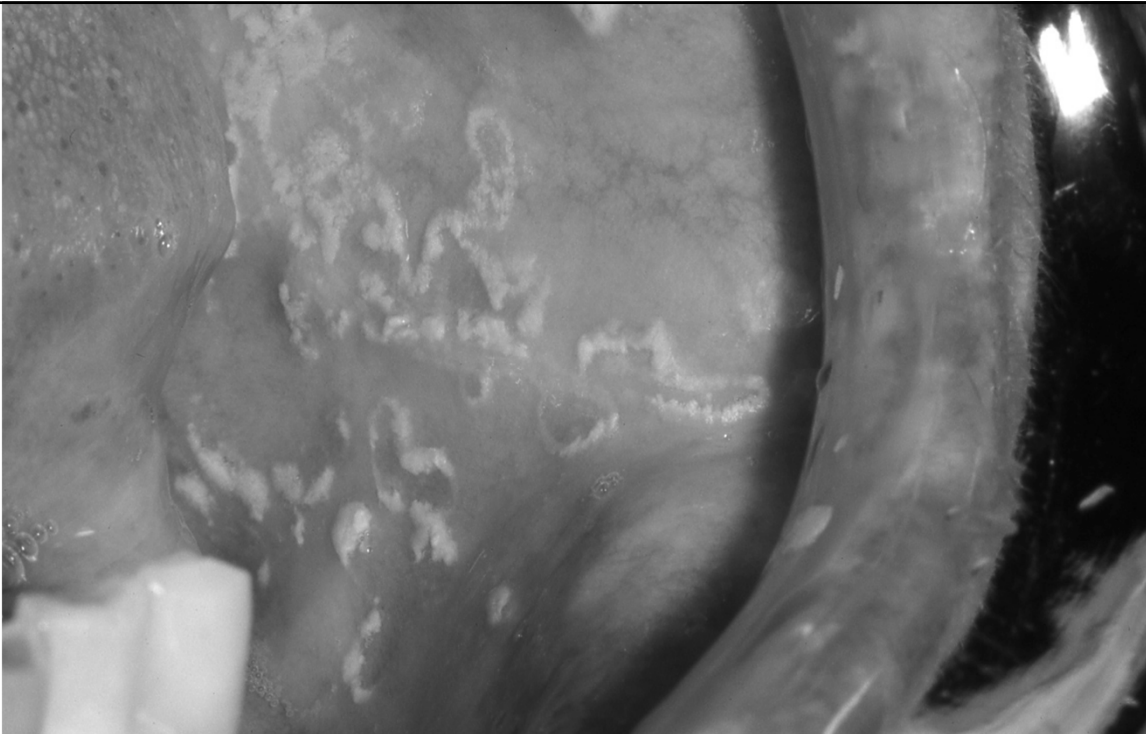- Candidiasis
  - Pseudomembranous candidiasis
  - Erythematous candidiasis
- Coated tongue
- Oral ulcers
  - Aphthous (canker sores)
  - Traumatic
  - Potentially neoplastic/precancerous

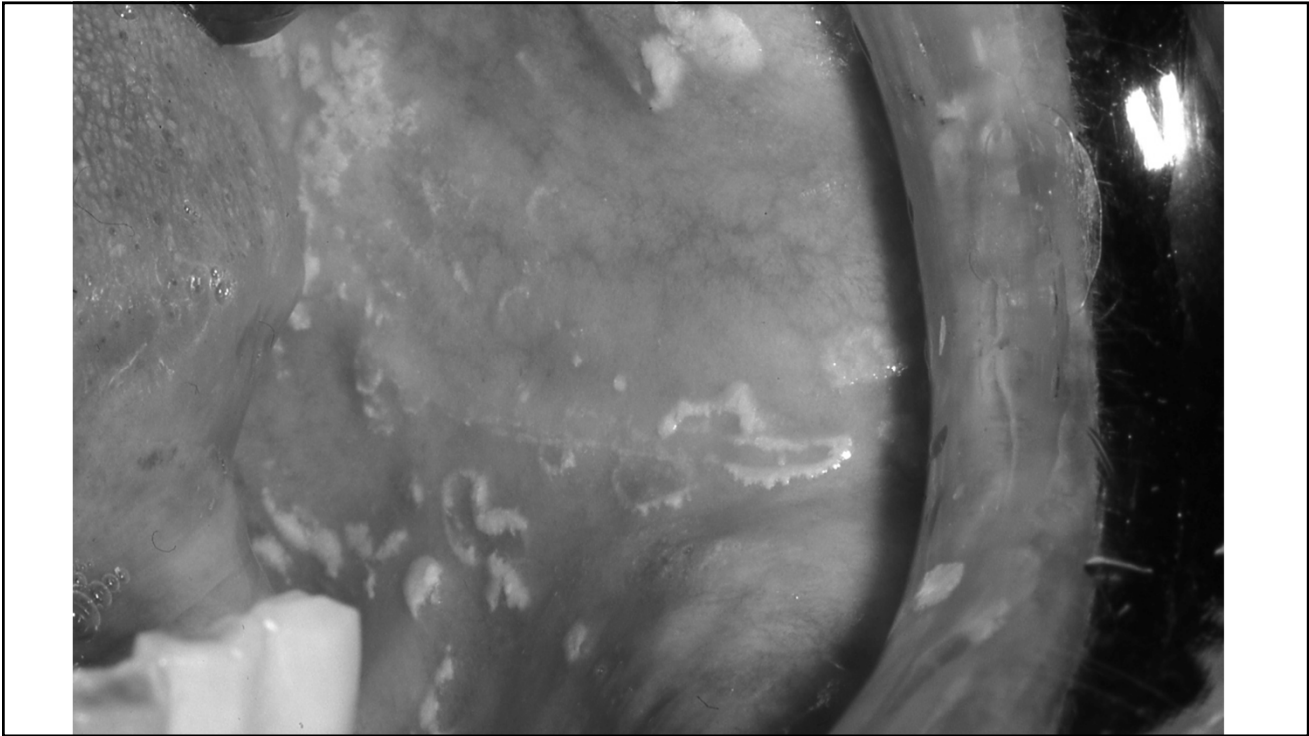
## Candida albicans

- Very common oral colonizer, may lead to infection
- Present in 30-50% of asymptomatic adults
- Presence in oral cavity increases with increasing patient age
- Multiple clinical presentations

## Pseudomembranous Candidiasis

- Also known as “thrush”
- White, curdled milk or cottage cheese-like plaques; can be wiped-off
- Common sites: buccal mucosa, palate or tongue
- May be asymptomatic, but burning or unpleasant taste occasionally noted





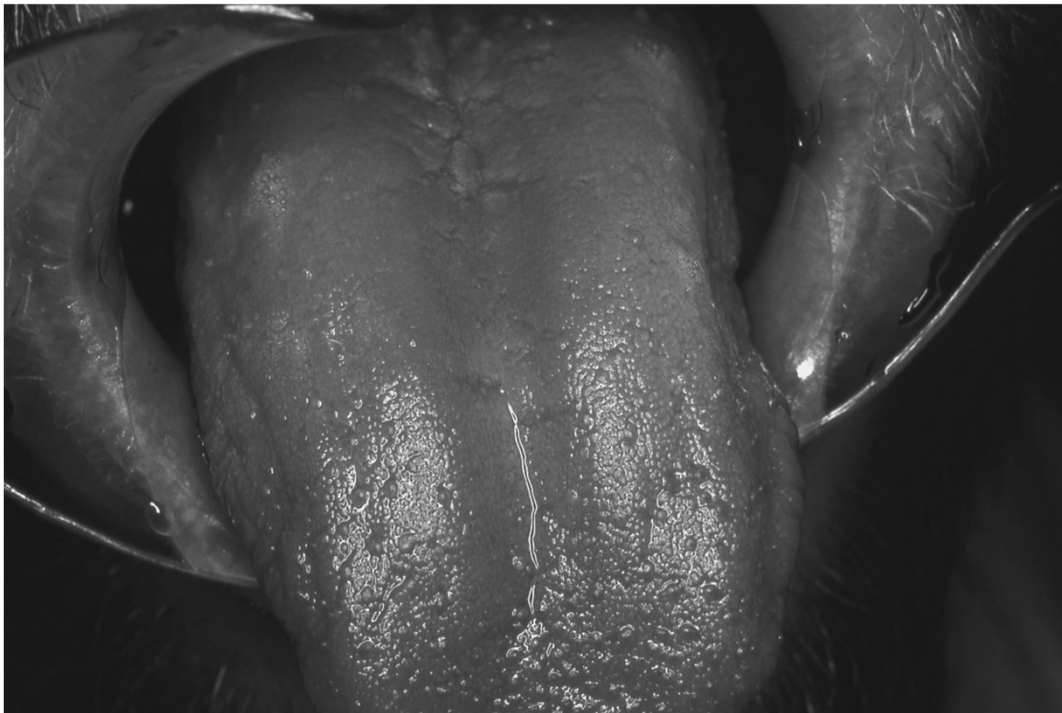## **Erythematous Candidiasis**

- more common than pseudomembranous candidiasis
- area of redness, variable borders
- dorsal tongue is common site
- may involve palate, oral commissures, perioral skin



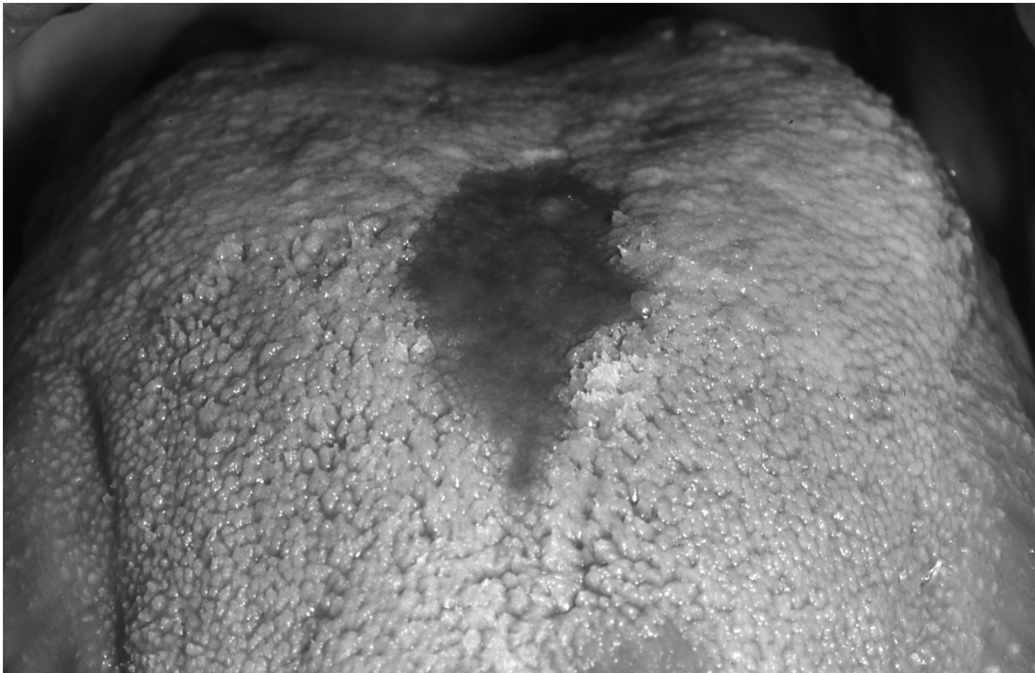
## **Acute atrophic candidiasis** ***aka “antibiotic sore mouth”***

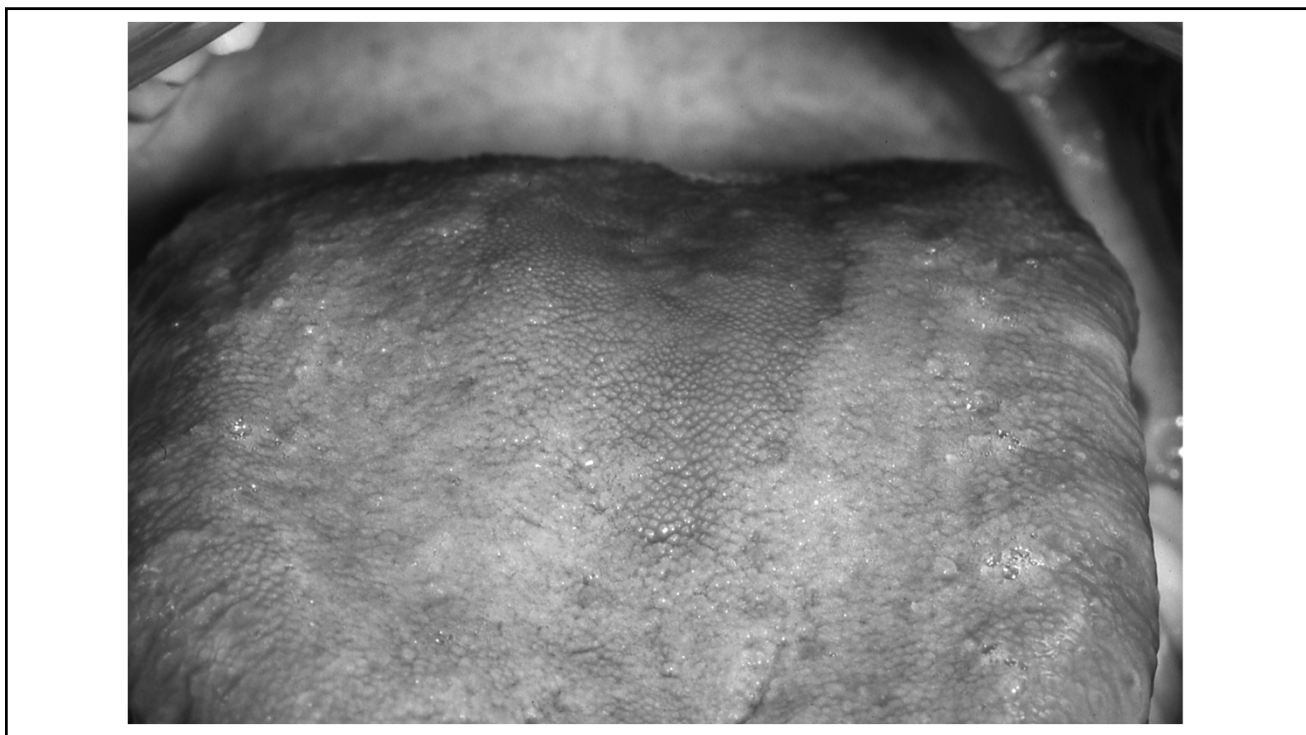
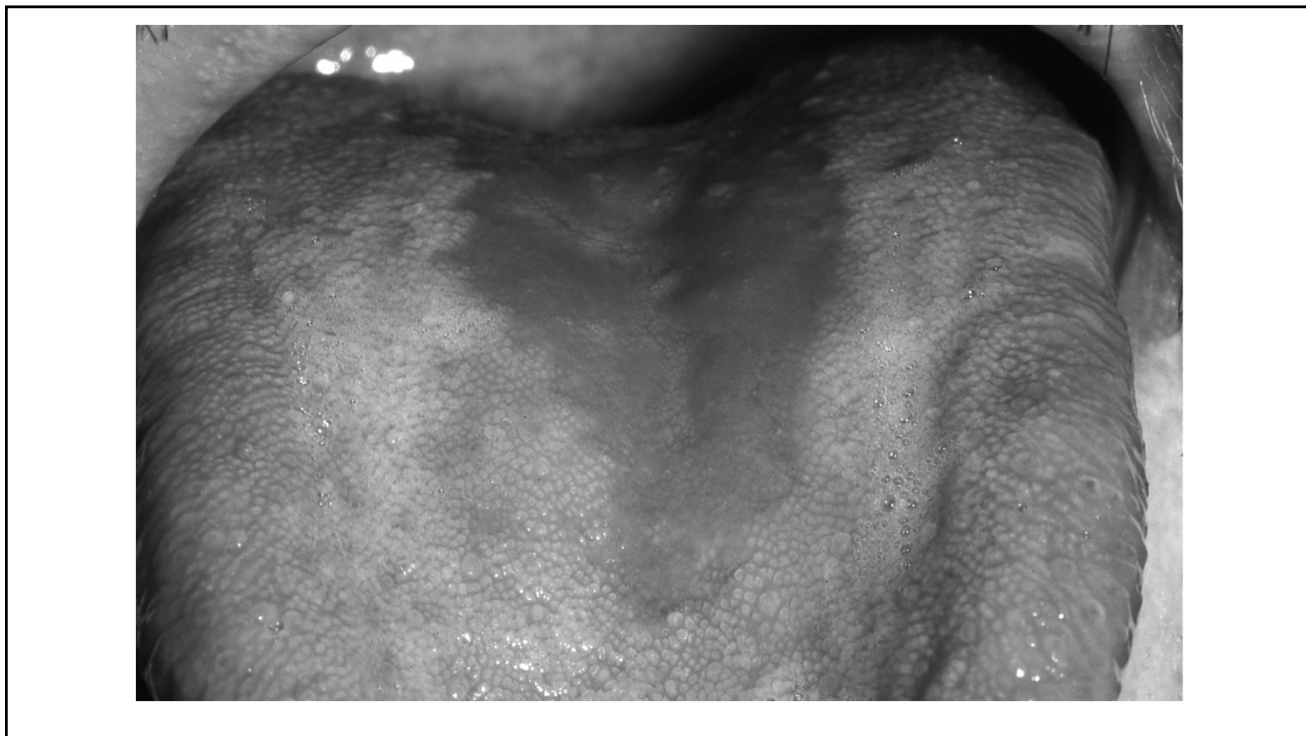
- diffuse atrophy of dorsal tongue papillae, particularly after broad-spectrum antibiotics
- acute onset
- typically associated with “burning” sensation



## Central Papillary Atrophy

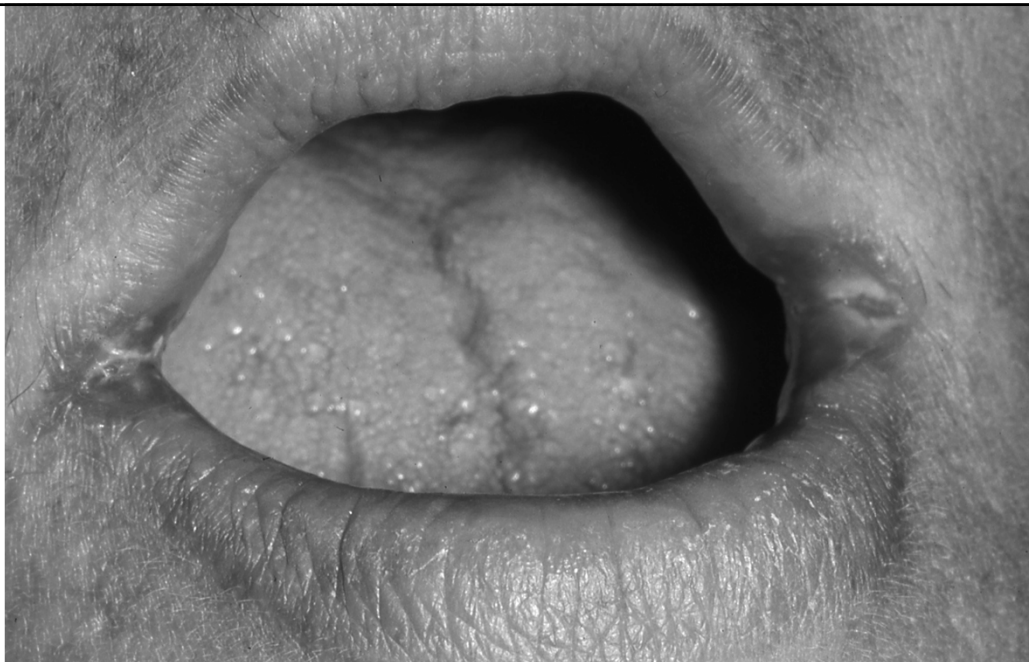
- Probably referred to as “median rhomboid glossitis” in the past
- Most are due to *chronic* candidiasis
- Well-defined area of redness, mid-posterior dorsal tongue
- Usually asymptomatic

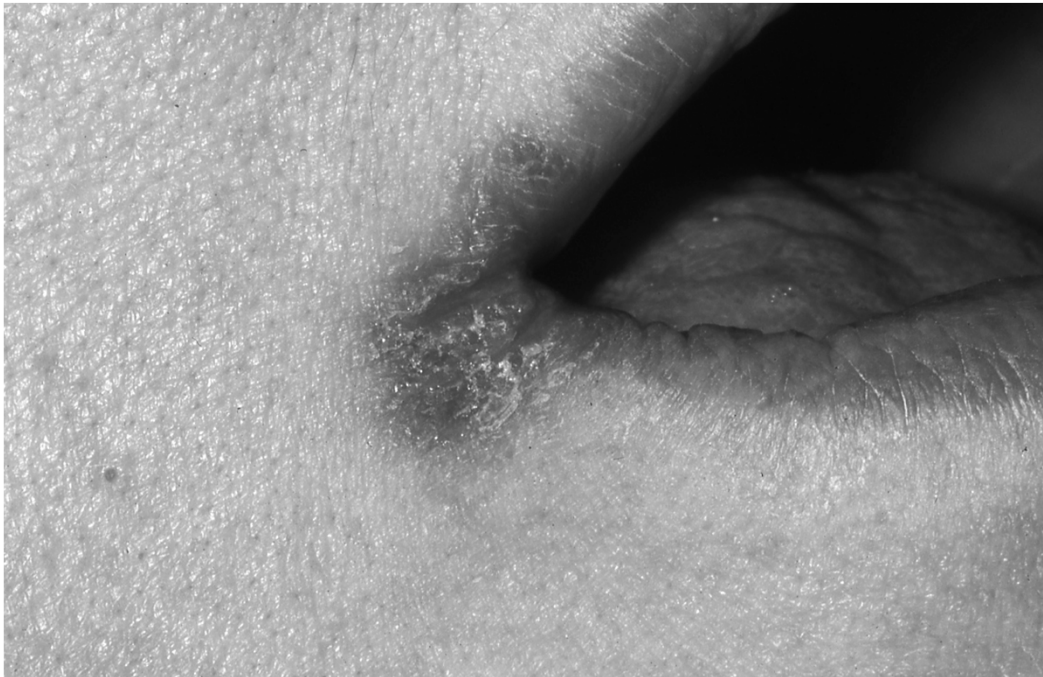



## Angular Cheilitis

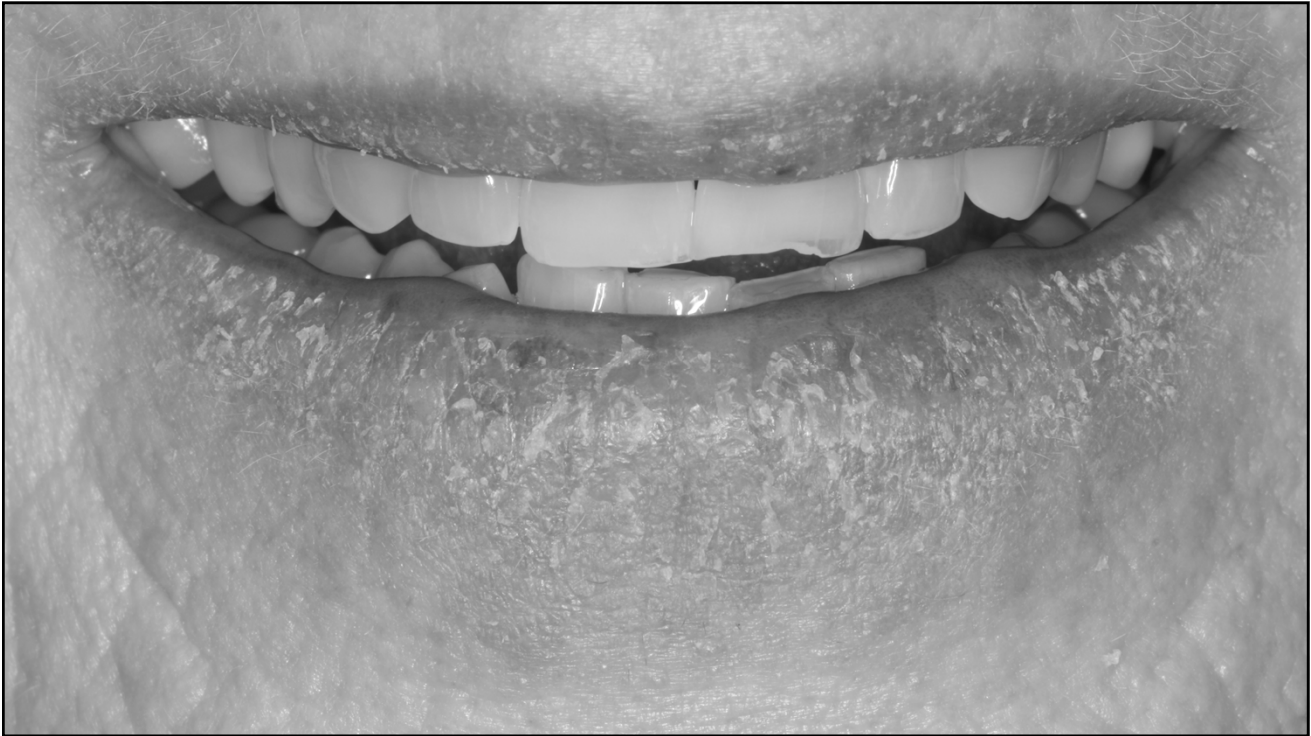- Usually related to candidiasis, but may have other cutaneous bacterial microflora admixed
- Often seen in patients with loss of posterior teeth; worn dentures or partials
- Redness, cracking of corners of mouth
- Typically responds well to topical antibiotics, but any intraoral infection must also be treated





## Perioral Candidiasis

- *Often associated with lip-licking or chronic use of petrolatum-based materials*
- *Usually related to candidiasis, but may have other cutaneous bacterial microflora admixed*
- *Redness, cracking of cutaneous surface*
- *Typically responds well to topical antifungal therapy*



## **Candidiasis: diagnosis**

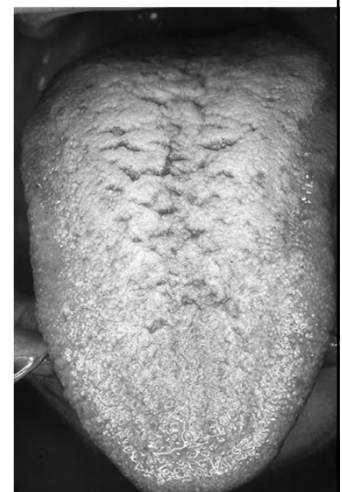
- Clinical signs and symptoms often sufficient
  - culture or exfoliative cytology
  - Biopsy – often unnecessary

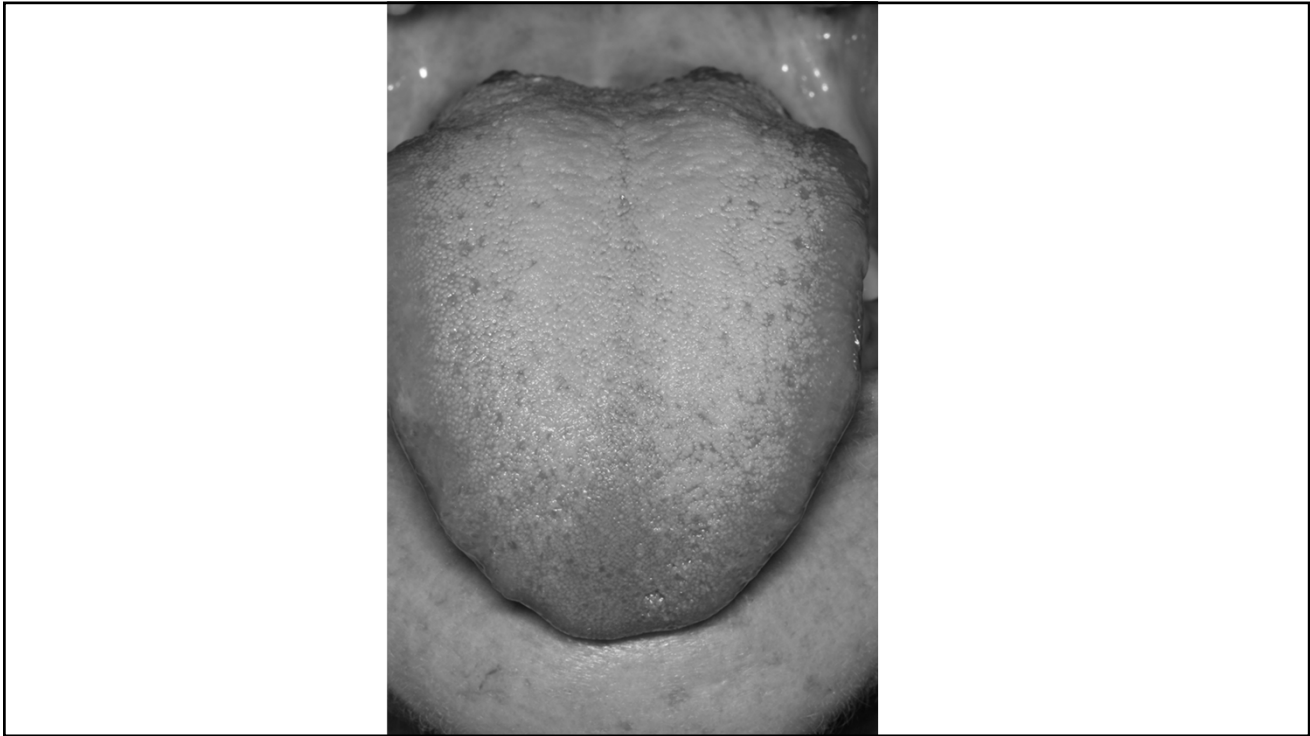
## Candidiasis: treatment

- Topical or systemic antifungal therapy
  - Clotrimazole troches (Mycelex)
  - Fluconazole tabs 100mg (Diflucan)
  - Iodoquinol/Hydrocortisone Cream (Dermazene) (angular cheilitis/perioral candidiasis; treats both fungi & bacteria)
- Removable prostheses (dentures) must also be cleaned and treated


## Coated Tongue (Hairy Tongue)

- Elongation of the filiform papillae on the dorsal tongue (accumulation of keratin)
  - Increased production keratin
  - Decreased removal keratin
- Often associated with smoking
- Asymptomatic





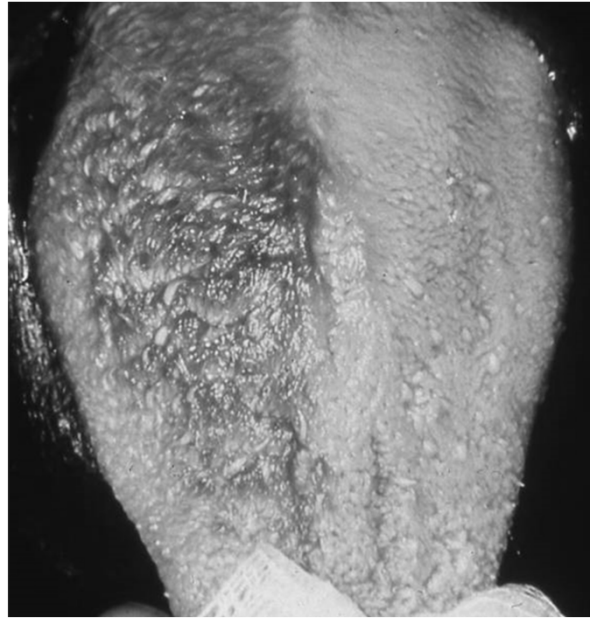
Papillae can become discolored  
pigment-producing bacteria vs. extrinsic staining





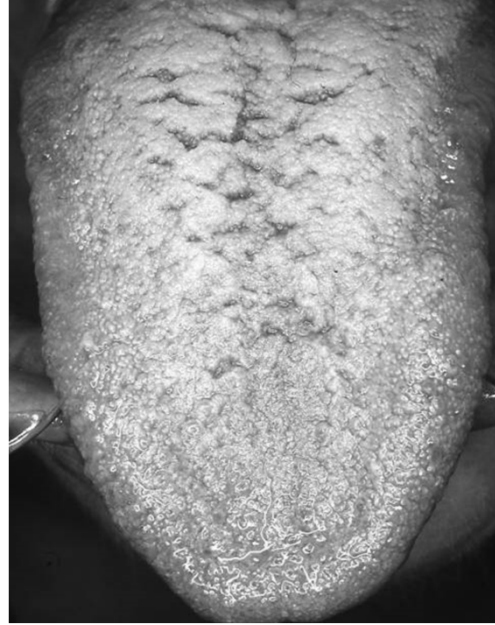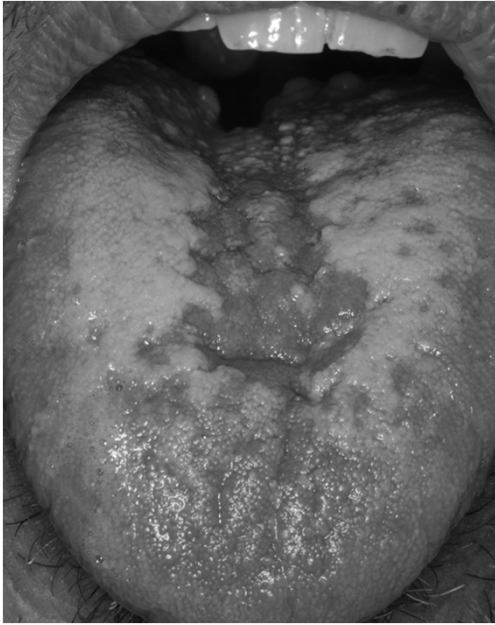## Treatment:

- None
- Tongue scraper



## Common pitfall...

- Don't confuse coated tongue for a yeast infection
- Candidiasis of the dorsal tongue generally appears RED (erythematous candidiasis- "***central papillary atrophy***")



## Candidiasis

- “Take home” message:
  - While pseudomembranous candidiasis may be the most widely-recognized form of oral candidiasis, it is **not** the most common.
  - Awareness of the various clinical presentations of oral candidiasis improves the likelihood of proper patient management.



# Oral Pathology for the Physician

**John R. Kalmar, DMD, PhD**

*Division of Oral and Maxillofacial Pathology  
The Ohio State University College of Dentistry  
kalmar.7@osu.edu*

**MedNet21**  
Center for Continuing Medical Education

 **THE OHIO STATE UNIVERSITY**  
WEXNER MEDICAL CENTER

## Objectives

- Review the clinical features of oral candidiasis
- Reinforce differentiation of oral candidiasis from coated tongue
- Review the clinical features of common oral ulcers
- Recognize the clinical features of potentially malignant oral lesions.
- Update management strategies

## Oral Ulcers

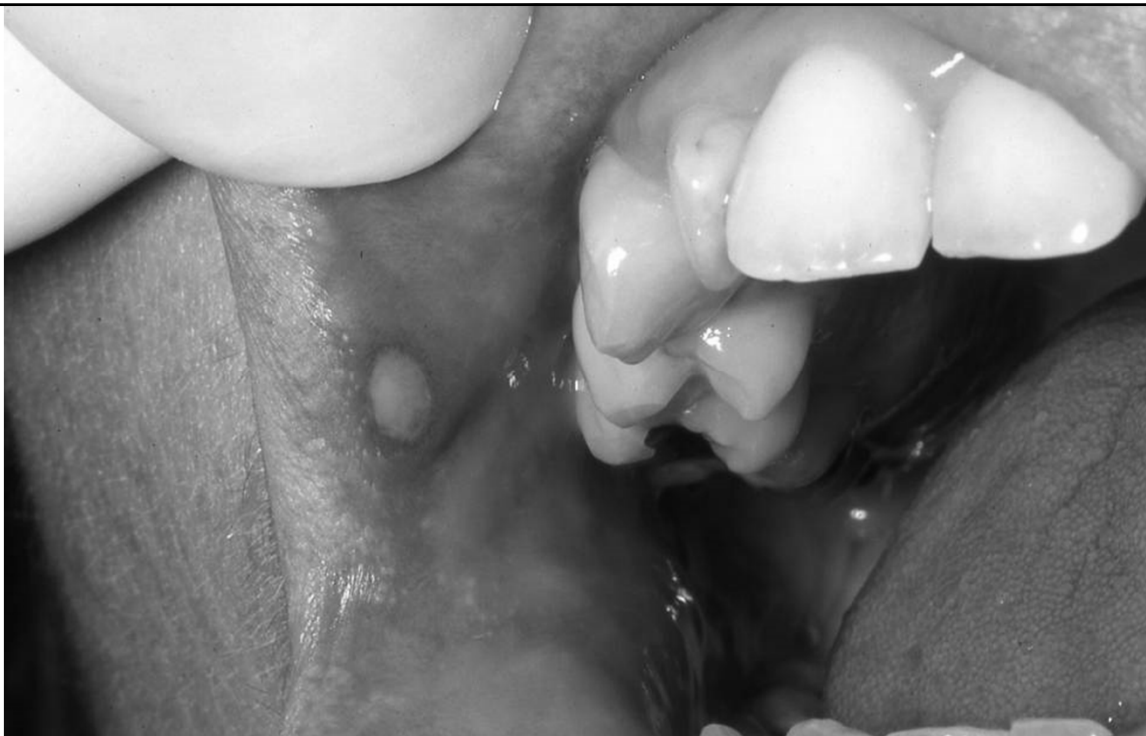- Immune-mediated (common to rare)
- Traumatic (common)
- Infectious (less common)
- Neoplastic (uncommon)

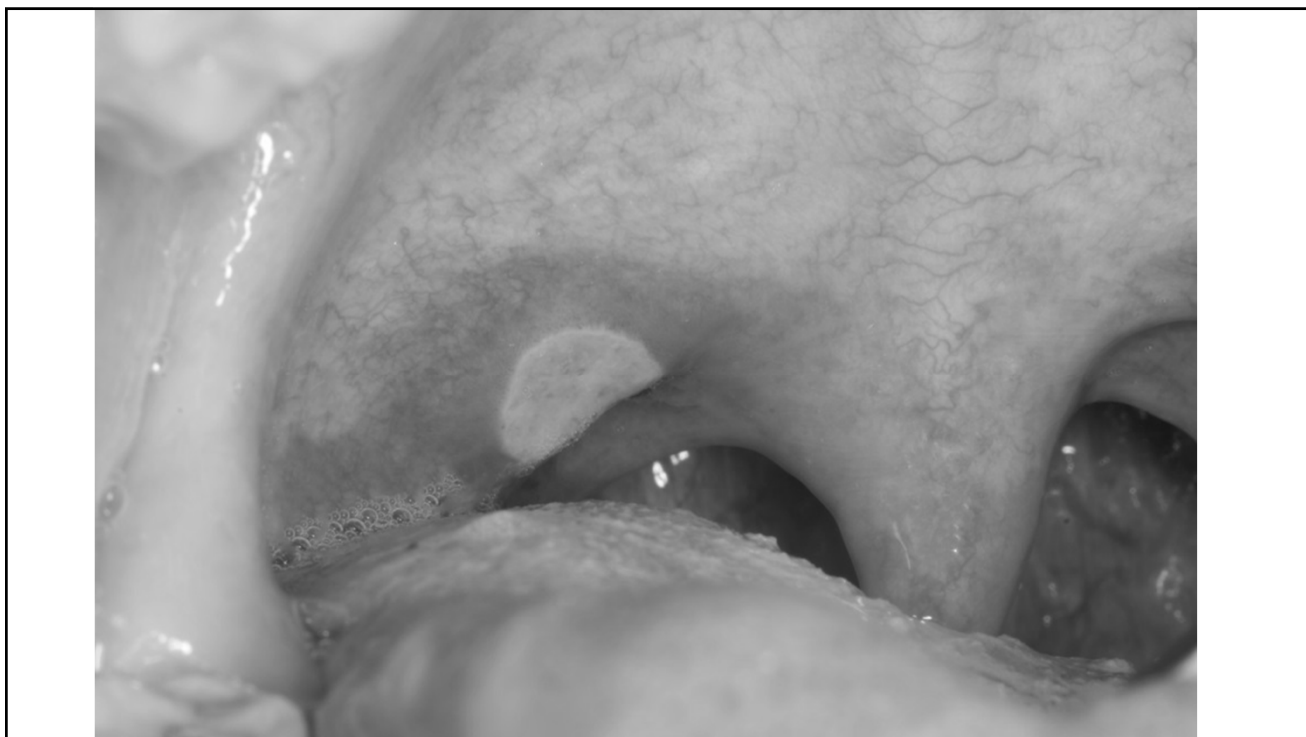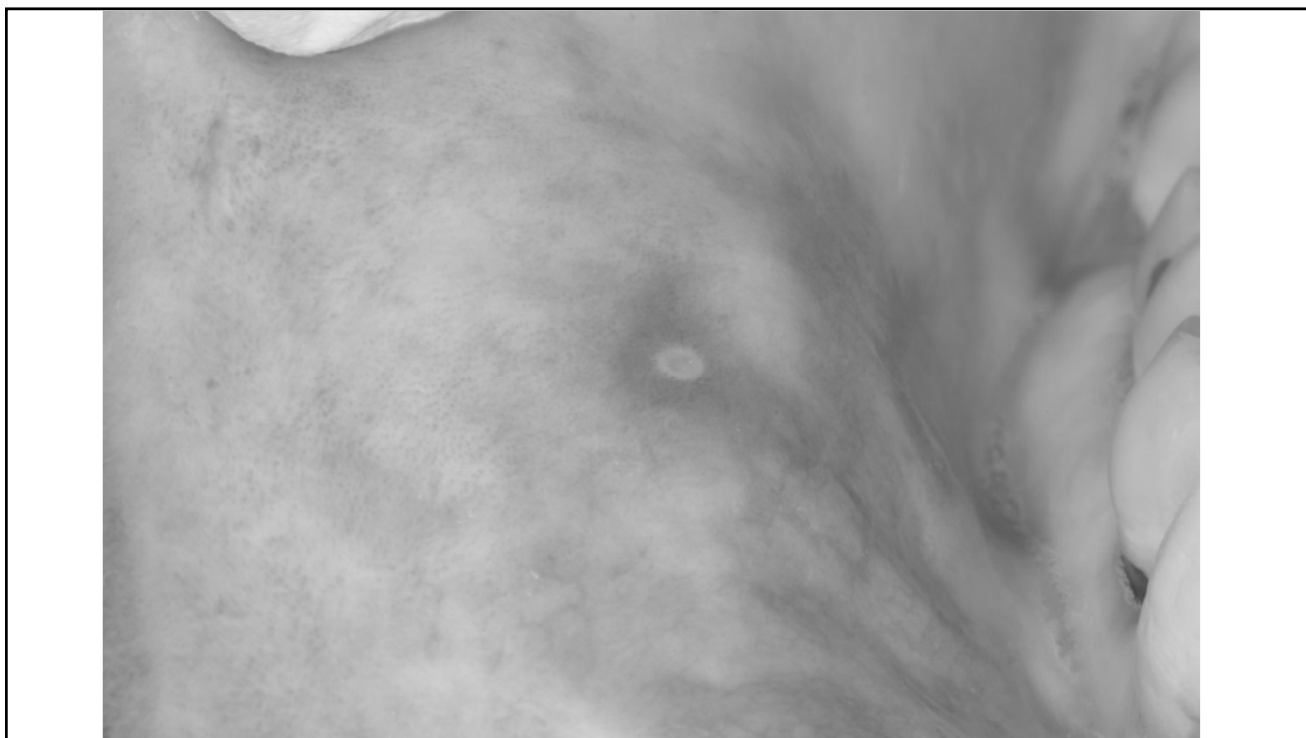
## Recurrent Aphthous Ulcerations (canker sores)

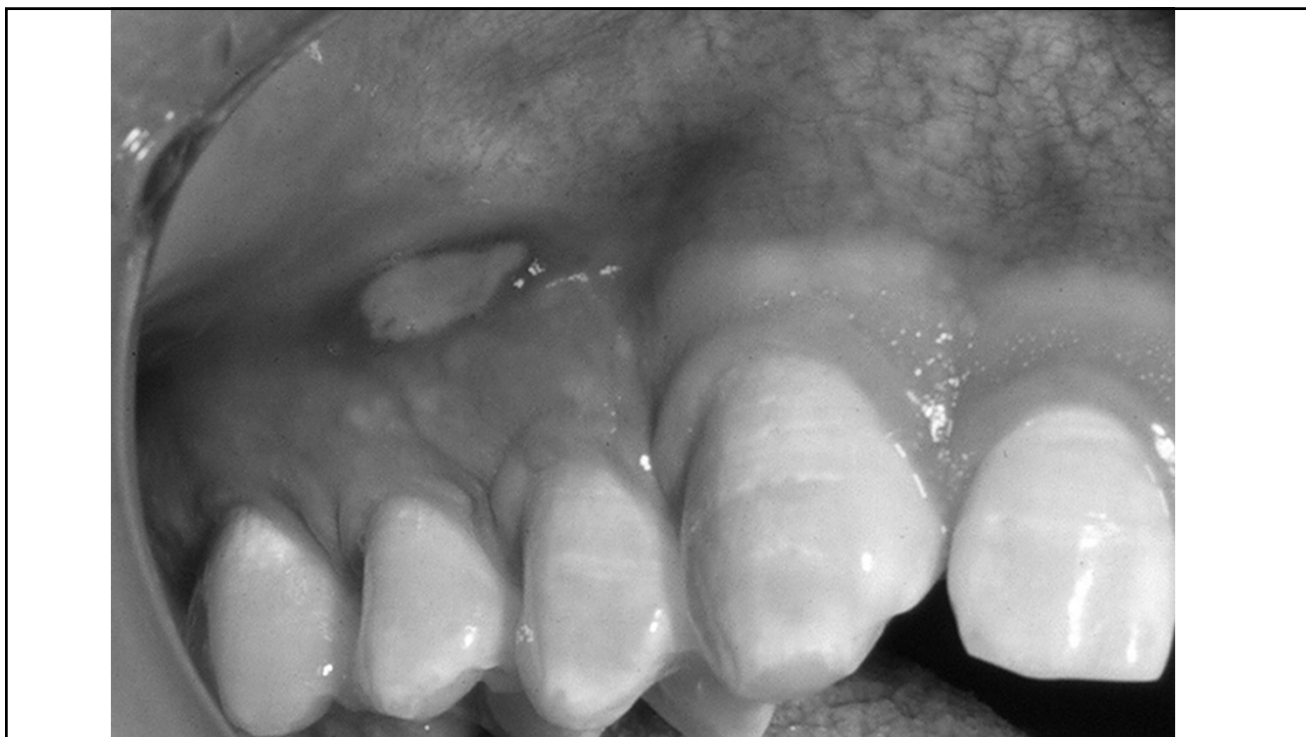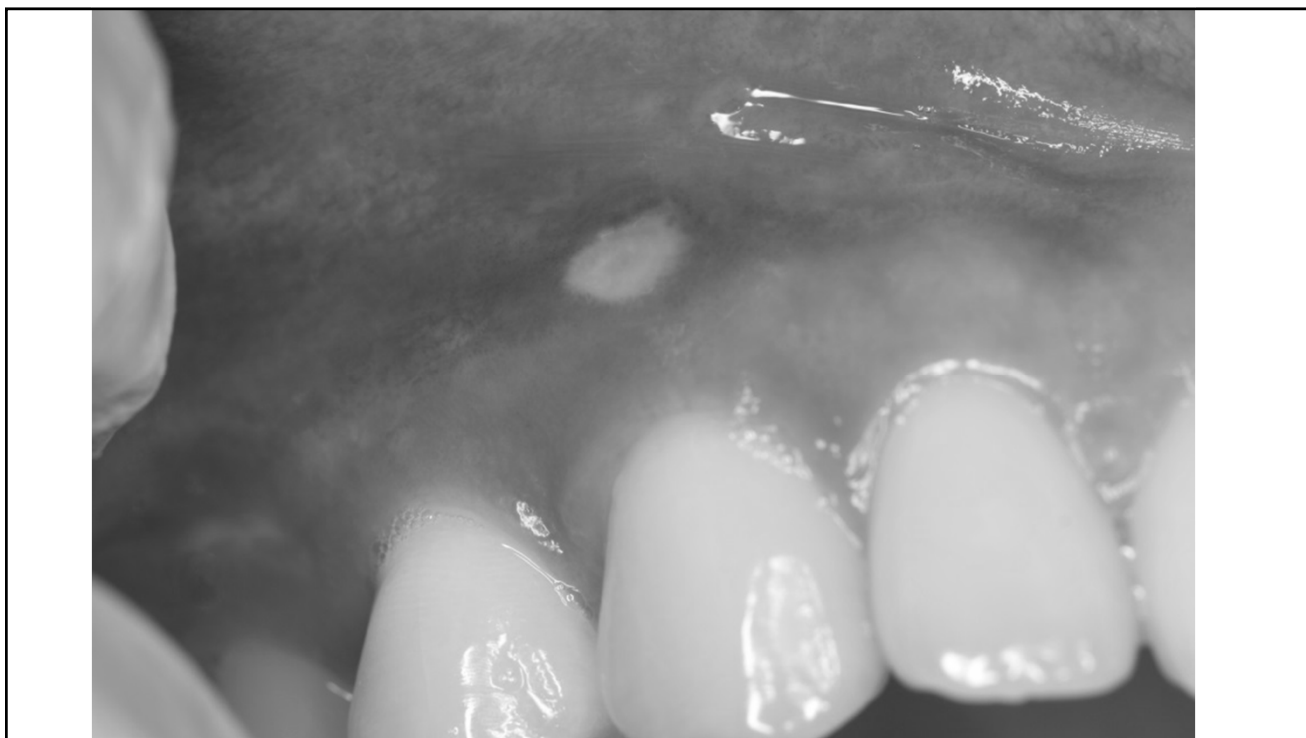
- Common (20% overall); familial relationship
- Most frequent in children and young adults
- Immune-mediated process; uncertain pathogenesis

## Recurrent Aphthous Ulcerations (canker sores)

- Prodromal dyesthesia/tingling common
- Occur on loose, nonkeratinized mucosa
- Extremely painful, round to oval shallow ulcers
- Early, erythematous halo







## Recurrent Aphthous Ulcerations

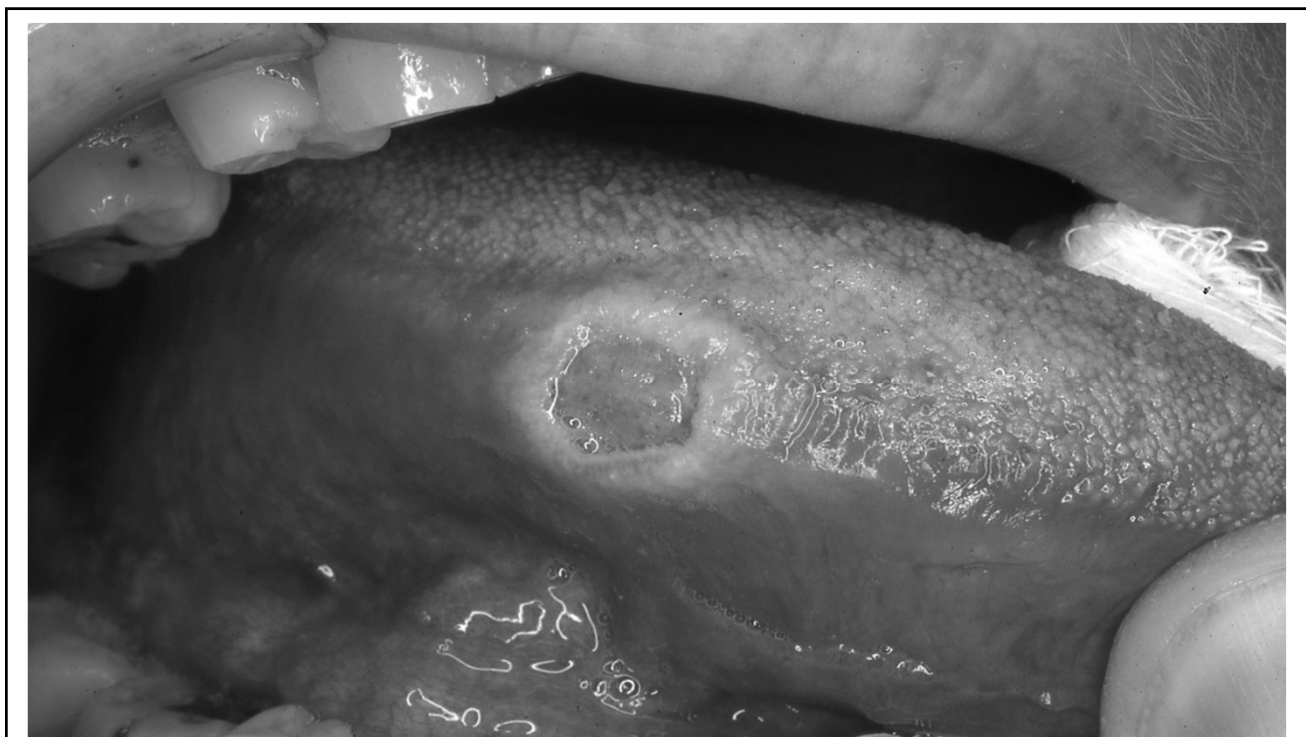
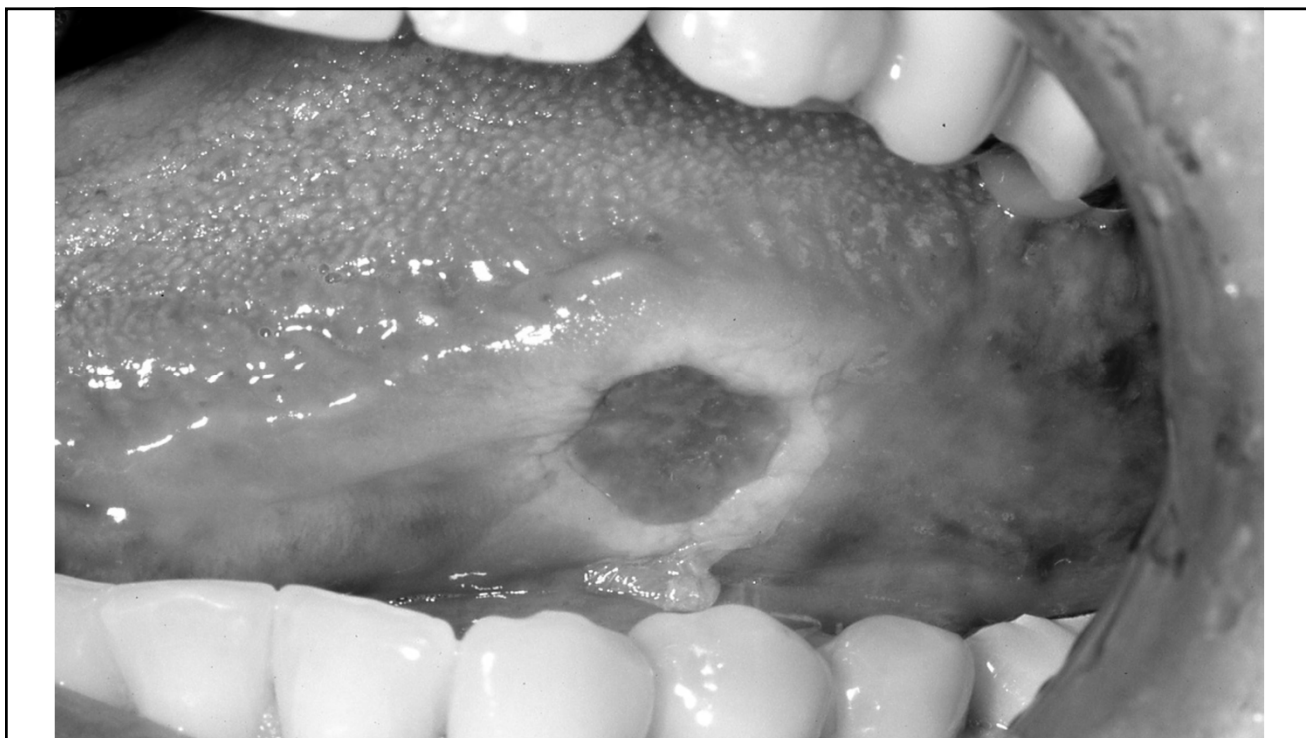
Treatment:

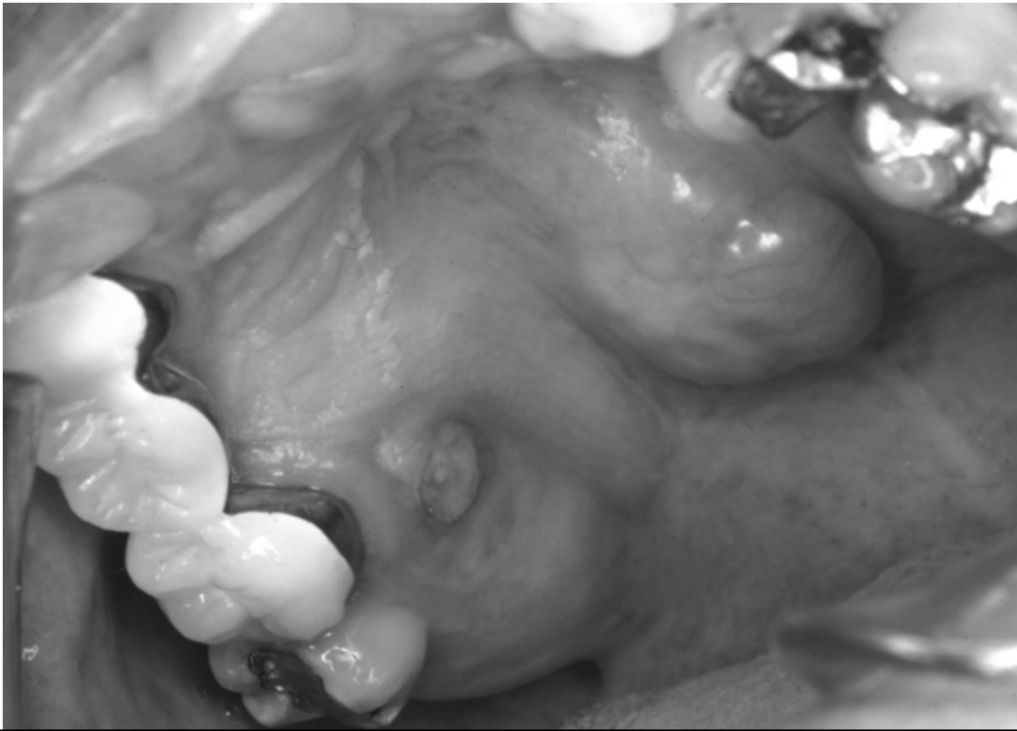
- Immune-basis responds well to topical high-potency corticosteroid gels
- Thin film, applied at earliest prodrome; multiple times (4X) per day

## Traumatic Ulcers

- Most common form of oral ulcer
- Occur in areas susceptible to trauma, especially from the teeth, or thermal injury from food or drink
- More common in patients with dry mouths
- Often asymptomatic or only mildly symptomatic

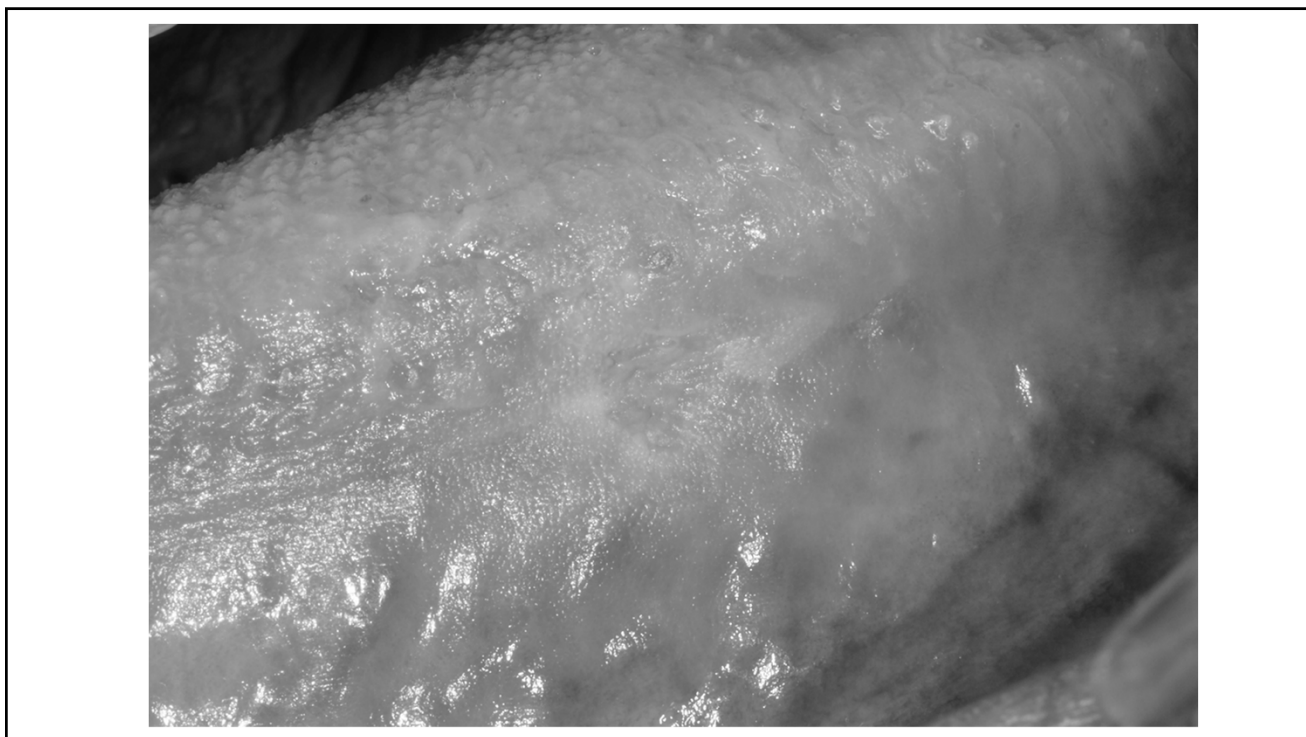
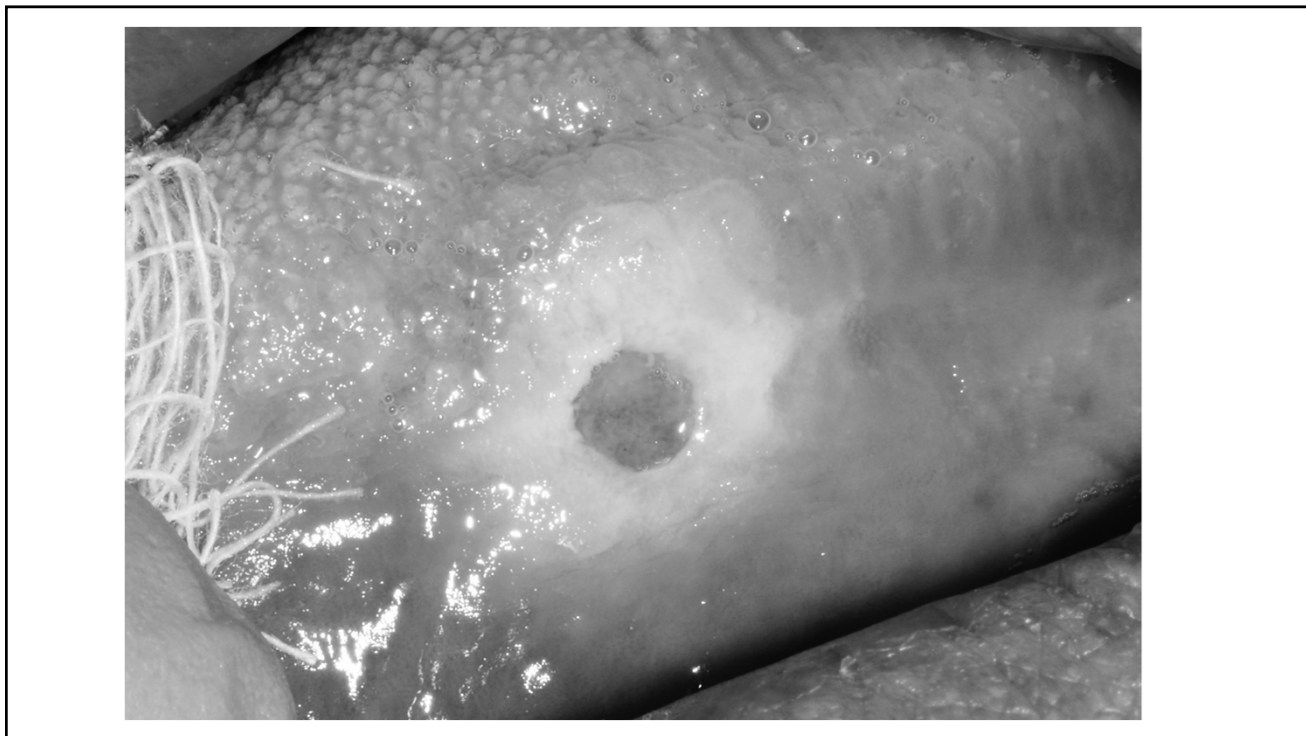






## Traumatic Ulcers

- Heal with no treatment (5-10 days) in the absence of additional irritation/trauma
- Topical OTC protective mucoadhesives can provide comfort
- Topical corticosteroids **not** indicated
  - Retard normal healing mechanisms
  - Can promote fungal infection, further slows healing



## Traumatic Ulcers

- Xerostomia can contribute to lesion persistence and also promotes candidal infection
- Patient should maintain adequate hydration
- Saliva substitutes or salivary stimulants can be helpful in moderate-severe cases of xerostomia

## Traumatic Ulcers

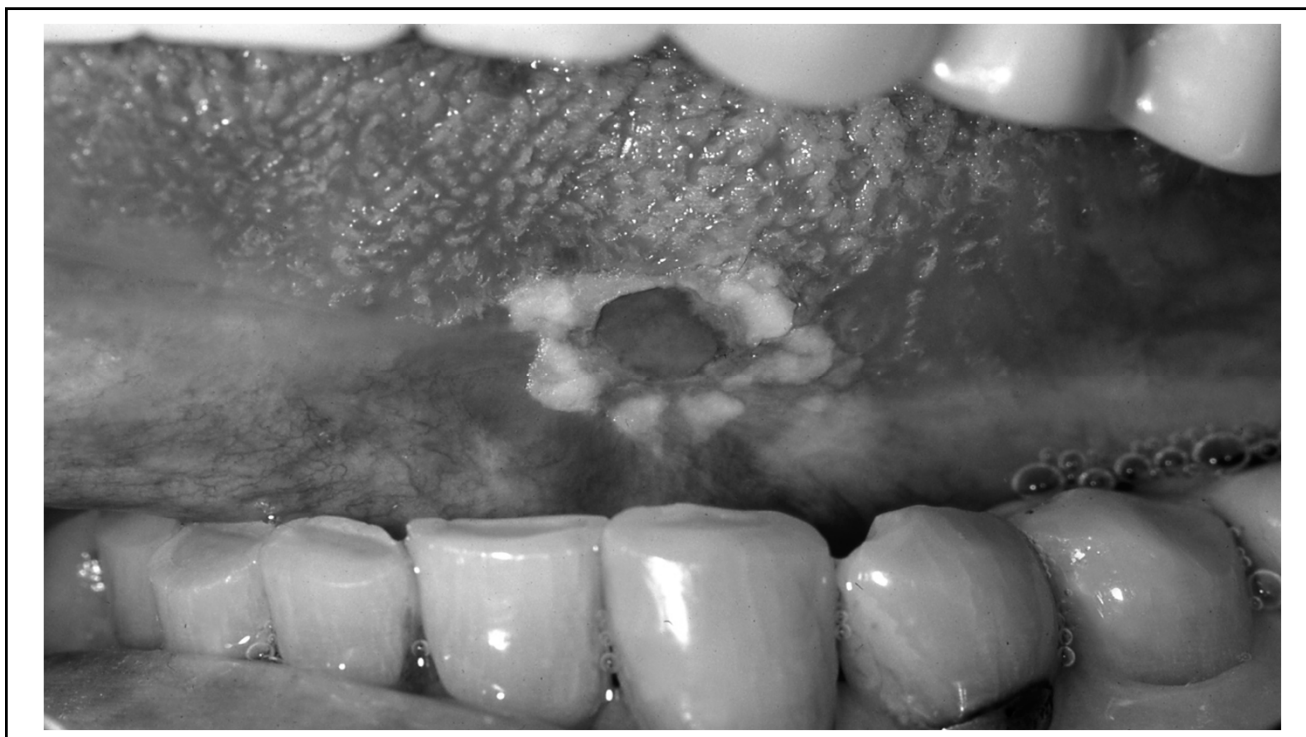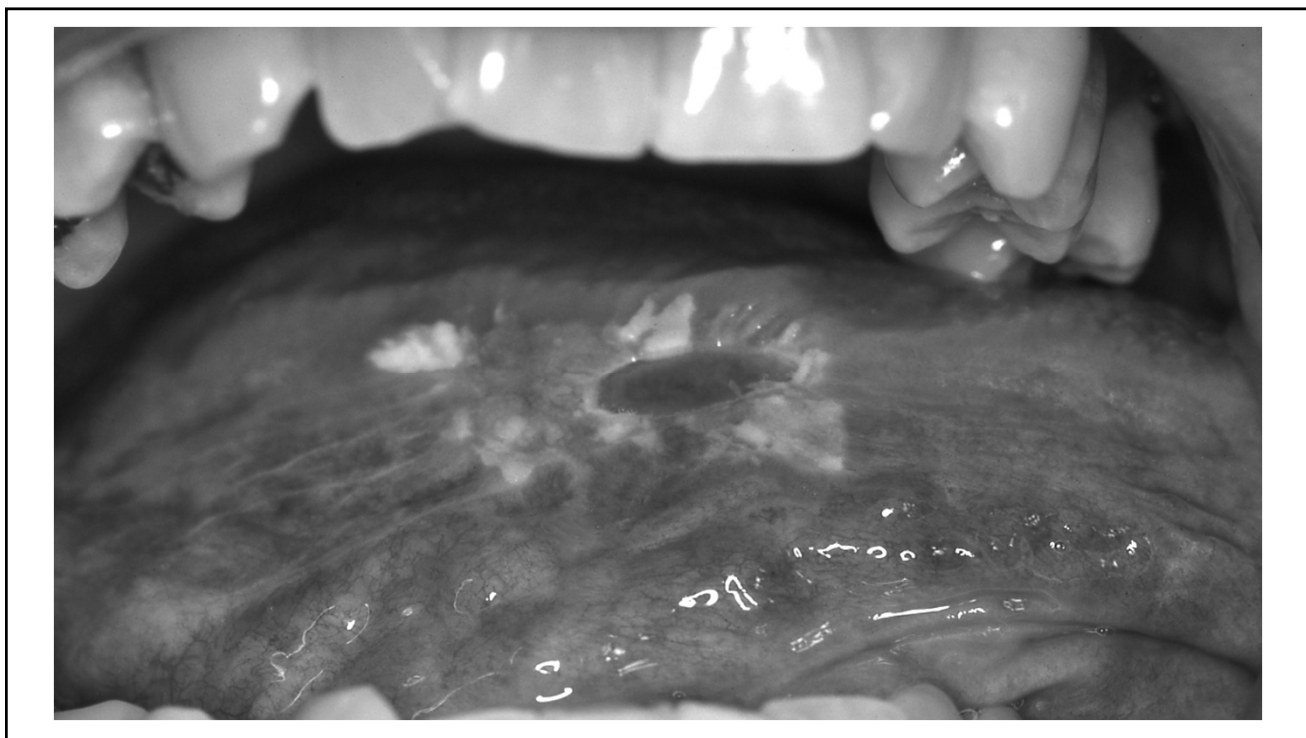- Follow-up warranted; 2-3 weeks
- If no evidence of healing, +/- conservative treatment measures, biopsy is usually warranted to establish a diagnosis and guide proper therapy

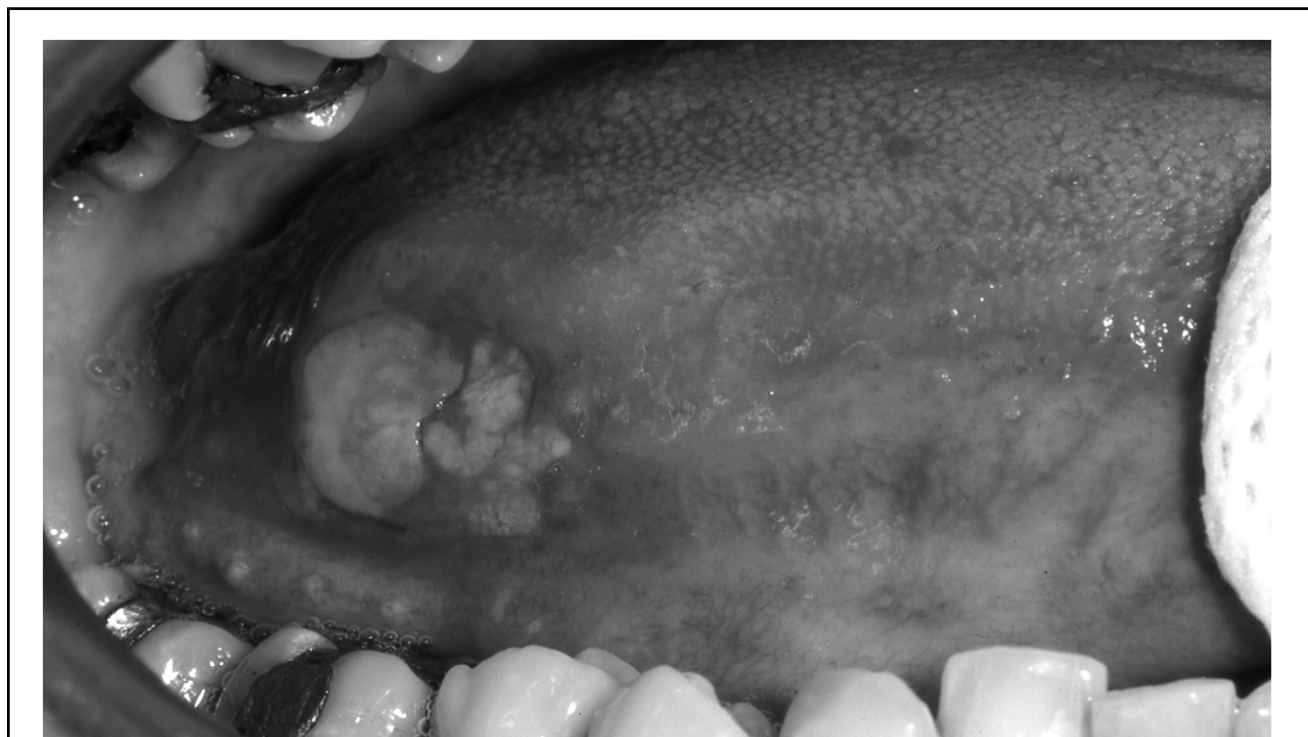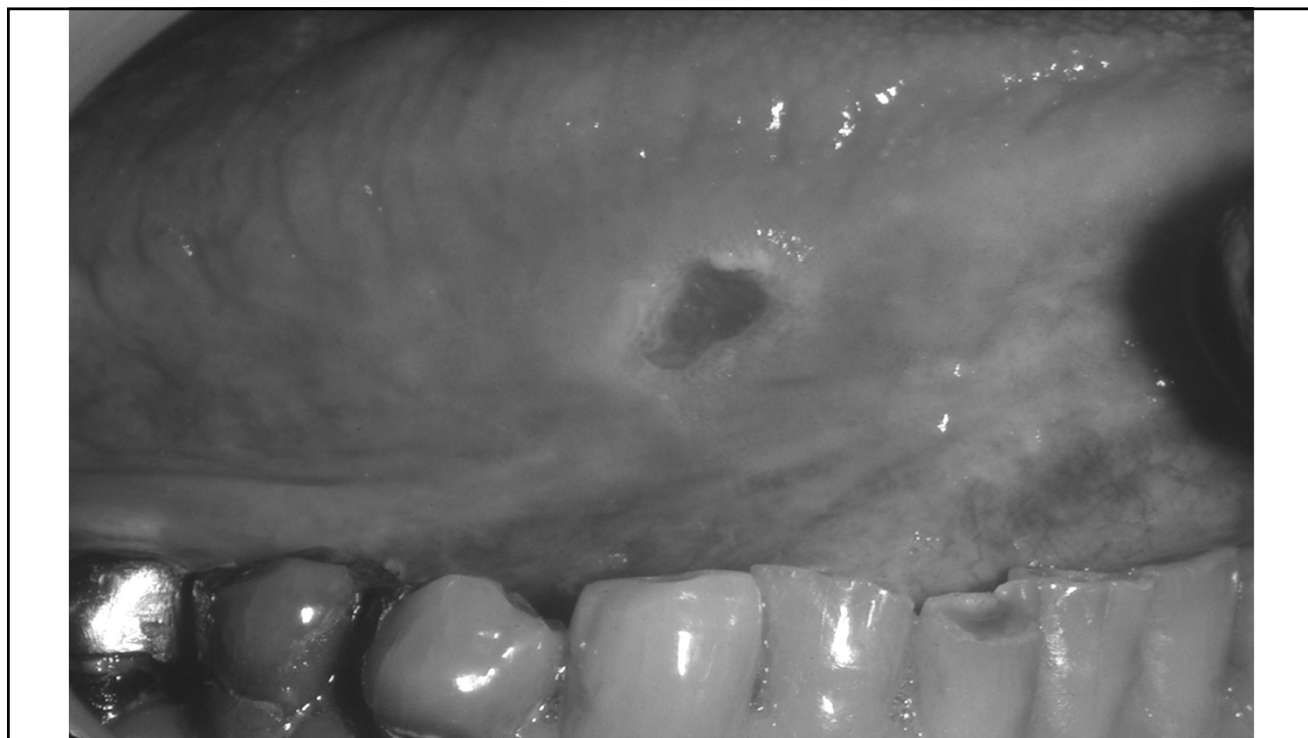
## Neoplastic Ulcers

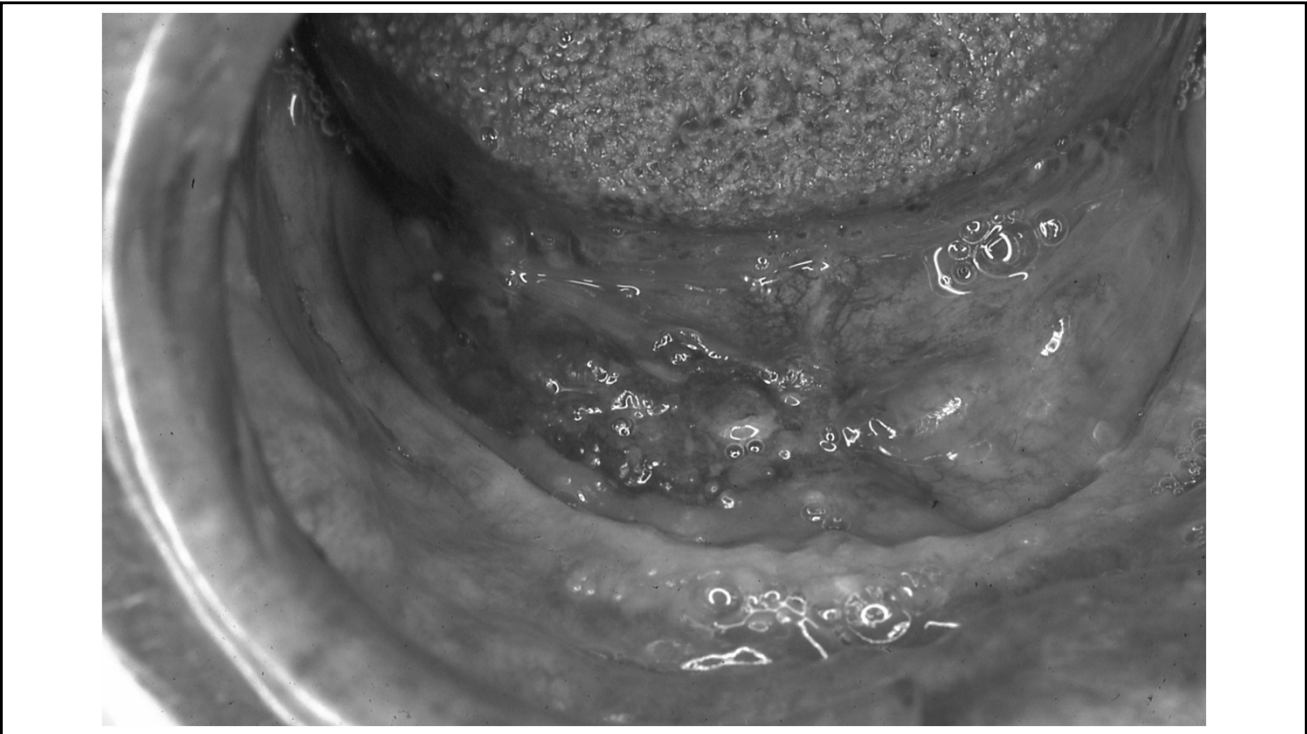
- Much less common than other types of oral ulcers, but more significant
- Majority (>90%) are due to surface precancerous lesions or squamous carcinoma

## Neoplastic Ulcers

- High-risk sites for oral squamous cell carcinoma include the ventrolateral tongue, lateral soft palate and floor of the mouth
- Tend to be chronic, often arise within pre-invasive lesions (leukoplakia/erythroplakia)
- Symptoms are variable, often asymptomatic







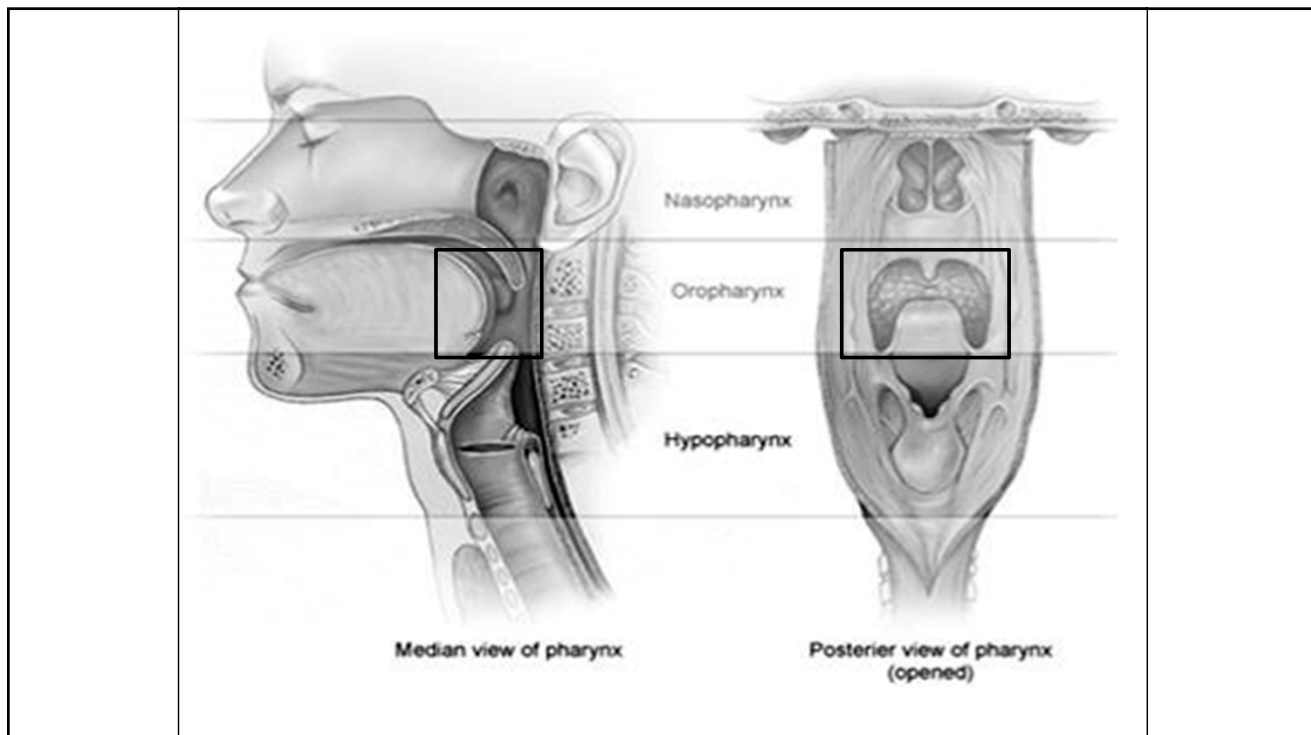
## Neoplastic Ulcers

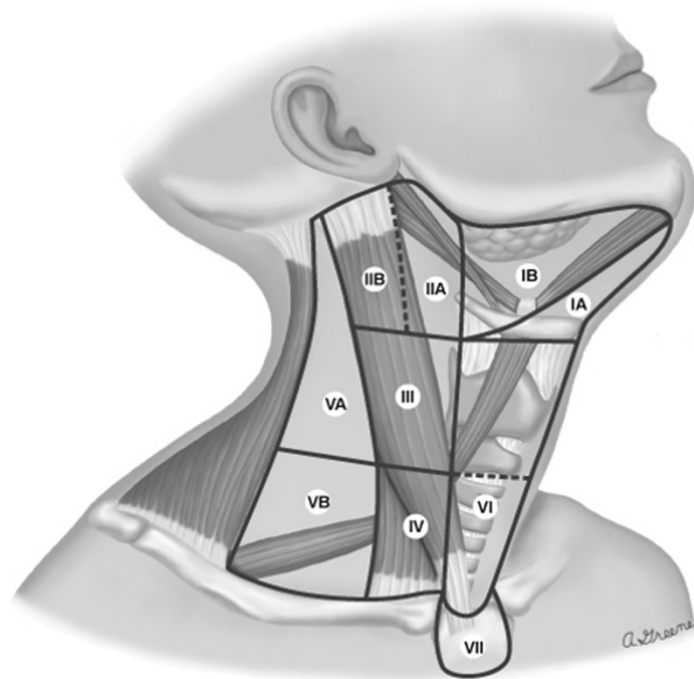
- “Take home” message:
  - If an ulcer persists for more than 2-3 weeks despite therapy/removal of potential irritants, biopsy should be recommended to establish a diagnosis and direct proper treatment



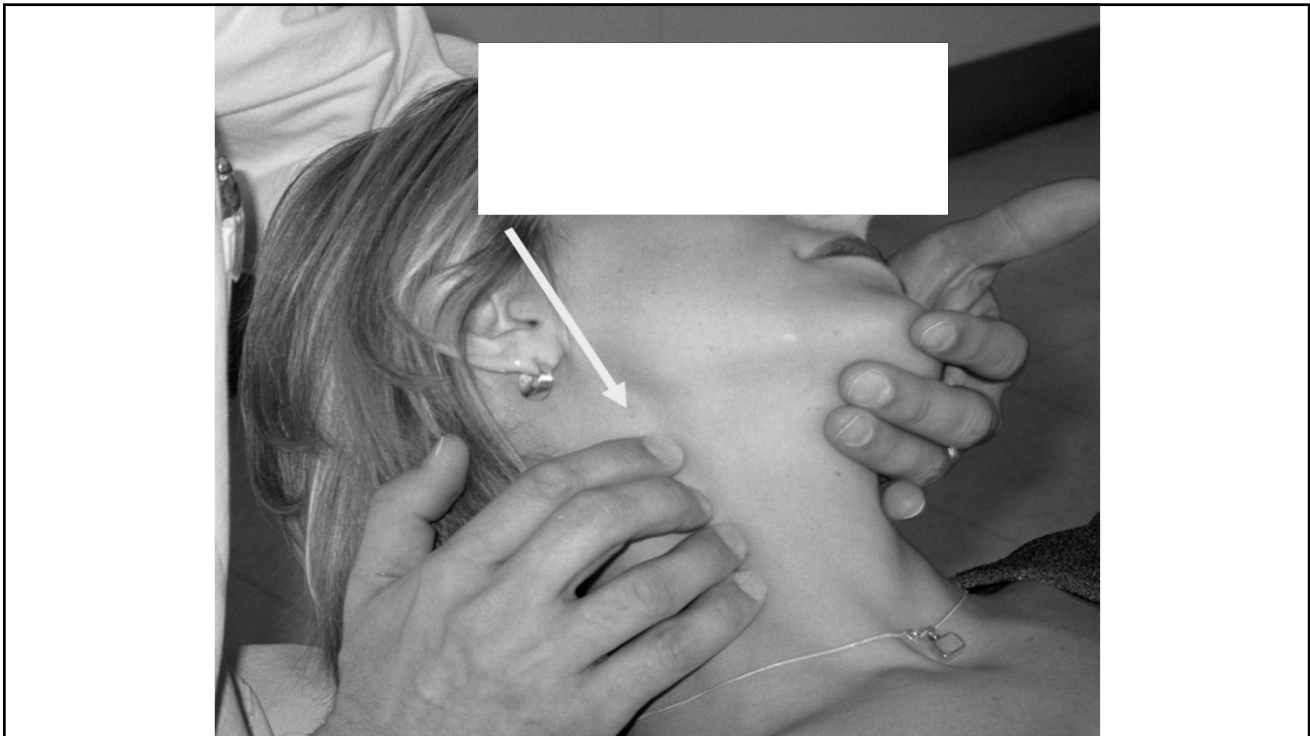## HPV-related Head & Neck Cancer

- ~90% of oropharyngeal/tonsillar carcinoma
- Increasing incidence over the past 20+ years
- Less frequent association with classic risk factors of smoking and alcohol use/abuse
- Most patients do not present with tonsillar mass or surface lesion
- Loco-regional metastases 1<sup>st</sup> clinical sign in 80-85% of patients, often level II or III





Bakshi, Jaimanti & Panda, Naresh & Mohammed, Abdul & Dash, Anil. (2016). neck dissection. - CC BY 3.0 DEED



## HPV-related Head & Neck Cancer

- Careful tactile examination for cervical or submandibular lymphadenopathy represents current clinical state-of-the-art in early diagnosis of HPV-related tonsillar cancer
- Subsequent FNA, biopsy and serologic testing for HPV ctDNA may be indicated to confirm suspicious adenopathy and direct therapy

- Special thanks for select clinical images to:
  - Carl Allen, Columbus, Ohio
  - Brad Neville, University of South Carolina
  - Doug Damm, Lexington, Kentucky
  - Philip Hawkins, Wauwatosa, Wisconsin